



ISUOG Practice Guidelines (updated): sonographic screening examination of the fetal heart

Clinical Standards Committee

The International Society of Ultrasound in Obstetrics and Gynecology (ISUOG) is a scientific organization that encourages safe clinical practice and high-quality teaching and research related to diagnostic imaging in women's healthcare. The ISUOG Clinical Standards Committee (CSC) has a remit to develop Practice Guidelines and Consensus Statements that provide healthcare practitioners with a consensus-based approach for diagnostic imaging. They are intended to reflect what is considered by ISUOG to be the best practice at the time at which they are issued. Although ISUOG has made every effort to ensure that Guidelines are accurate when issued, neither the Society nor any of its employees or members accept any liability for the consequences of any inaccurate or misleading data, opinions or statements issued by the CSC. The ISUOG CSC documents are not intended to establish a legal standard of care because interpretation of the evidence that underpins the Guidelines may be influenced by individual circumstances, local protocol and available resources. Approved Guidelines can be distributed freely with the permission of ISUOG (info@isuog.org).

INTRODUCTION

This document constitutes a revised and updated version of the previously published ISUOG guidelines for cardiac screening in midgestation¹ and reflects current knowledge about prenatal detection of congenital heart disease (CHD). The new ISUOG recommendation that outflow tract views as well as the four-chamber view be added to routine screening is evidence-based and parallels recent guidelines and recommendations from other professional bodies^{2–5}.

CHD is a leading cause of infant mortality, with an estimated incidence of about 4–13 per 1000 live births^{6–8}. Between 1950 and 1994, 42% of infant deaths reported to the World Health Organization were attributable to cardiac defects⁹. Structural cardiac anomalies were also among the abnormalities most frequently missed by prenatal ultrasonography^{10,11}. Prenatal detection of CHD may improve the outcome of fetuses with specific types of cardiac lesions^{12–16}, but prenatal detection rates

vary widely¹⁷. Some of this variation can be attributed to differences in examiner experience, maternal obesity, transducer frequency, abdominal scars, gestational age, amniotic fluid volume and fetal position^{18,19}. Continuous feedback-based training of healthcare professionals, a low threshold for echocardiography referrals and convenient access to fetal heart specialists are particularly important factors that can improve the effectiveness of a screening program^{8,20}. As one example, the detection rate of major cardiac anomalies doubled after implementation of a 2-year training program at a medical facility in Northern England²¹.

The cardiac screening examination of the fetus is designed to maximize the detection of heart anomalies during a second-trimester scan²². These Guidelines can be used in the evaluation of low-risk fetuses examined as part of routine prenatal care^{23–25}. This approach also helps to identify fetuses at risk for genetic syndromes and provides useful information for patient counseling, obstetric management and multidisciplinary care. Suspected heart anomalies will require more comprehensive evaluation using fetal echocardiography²⁶.

GENERAL CONSIDERATIONS

Despite the well-documented utility of the four-chamber and outflow tract views, one should be aware of the potential diagnostic pitfalls that can prevent timely detection of CHD^{27–29}. Detection rates can be optimized by performing a thorough screening examination of the heart, recognizing that the four-chamber view is much more than a simple count of cardiac chambers, understanding that some lesions are not discovered until later in pregnancy, and being aware that specific types of abnormalities (e.g. transposition of the great arteries or aortic coarctation) may not be evident from the four-chamber plane alone. Complementing the four-chamber view with the outflow tract views in the cardiac screening examination is therefore an important step to improve detection of CHD.

Gestational age

The cardiac screening examination is performed optimally between 18 and 22 weeks' menstrual age, although many

anatomical structures can still be visualized satisfactorily beyond 22 weeks. Some anomalies may be identified during the late first and early second trimesters of pregnancy, especially when increased nuchal translucency thickness is identified^{30–35}. Screening at 20–22 weeks' gestation is less likely to require an additional scan for completion of this evaluation, although many patients would prefer to know about major defects at an earlier stage of pregnancy³⁶.

Technical factors

Ultrasound transducer

Higher-frequency probes will improve the likelihood of detecting subtle defects, at the expense of reduced acoustic penetration. The highest possible transducer frequency should be used for all examinations, recognizing the trade-off between penetration and resolution. Harmonic imaging may provide improved images, especially for patients with increased maternal abdominal wall thickness during the third trimester of pregnancy³⁷.

Imaging parameters

Cross-sectional gray-scale imaging is still the basis of a reliable fetal cardiac scan. System settings should emphasize a high frame rate, with increased contrast and high resolution. Low persistence, a single acoustic focal zone and a relatively narrow image field should also be used.

Zoom and cine-loop

Images should be magnified until the heart fills at least one third to one half of the screen. The cine-loop feature should be used to assist the real-time evaluation of normal cardiac structures, for example, to confirm movement of heart valve leaflets throughout the cardiac cycle. Image magnification and use of cine-loop may help in identifying abnormalities.

CARDIAC EXAMINATION

Considering the time elapsed since the publication of the initial ISUOG guidelines¹, and recent evidence from the literature, the cardiac screening examination should now include both the four-chamber and outflow tract views^{38–46}.

Four-chamber view

The four-chamber view involves careful evaluation of specific criteria and should not be mistaken for a simple chamber count. The main elements for examination of the four chambers are shown in Table 1 and Figures 1 and 2. To assess cardiac situs, it is necessary that fetal laterality i.e. identification of fetal right and left sides, be

Table 1 Assessment of fetal situs/laterality and the four-chamber view

Situs and general aspects	
Fetal laterality (identify right and left sides of fetus)	
Stomach and heart on left	
Heart occupies a third of thoracic area	
Majority of heart in left chest	
Cardiac axis (apex) points to left by $45^\circ \pm 20^\circ$	
Four chambers present	
Regular cardiac rhythm	
No pericardial effusion	
Atrial chambers	
Two atria, approximately equal in size	
Foramen ovale flap in left atrium	
Atrial septum primum present (near to crux)	
Pulmonary veins entering left atrium	
Ventricular chambers	
Two ventricles, approximately equal in size	
No ventricular wall hypertrophy	
Moderator band at right ventricular apex	
Ventricular septum intact (apex to crux)	
Atrioventricular junction and valves	
Intact cardiac crux	
Two atrioventricular valves open and move freely	
Differential offsetting: tricuspid valve leaflet inserts on ventricular septum closer to cardiac apex than does mitral valve	

determined first, prior to ascertaining that both stomach and heart are on the left side of the fetus. A normal heart is usually no larger than one third of the area of the chest. Some views may reveal a small hypoechogenic rim around the fetal heart, which can be mistaken for a pericardial effusion. An isolated finding of this type usually represents a normal variation^{47,48}.

The heart is mainly situated on the left side of the chest and its long axis normally points to the left by about $45 \pm 20^\circ$ (2 SD)⁴⁹ (Figure 1). Careful attention should be paid to cardiac axis and position, which can be evaluated easily even if the four-chamber view is not visualized satisfactorily⁵⁰. Situs abnormalities should be suspected when the fetal heart and/or stomach are not found on the left side. Abnormal axis increases the risk of a cardiac malformation, especially involving the outflow tracts. This finding may also be associated with a chromosomal anomaly. Abnormal displacement of the heart from its normal anterior left position can be caused by a diaphragmatic hernia or space-occupying lesion, such as cystic adenomatoid malformation of the lung. Position abnormalities can also be secondary to fetal lung hypoplasia or agenesis. A shift of the axis to the left may also occur with fetal gastroschisis and omphalocele.

Normal heart rate and regular rhythm should be confirmed. The normal rate ranges from 120 to 160 beats per minute (bpm). Mild bradycardia is observed transiently in normal second-trimester fetuses. Fixed bradycardia, especially heart rates that remain below 110 bpm⁵¹, requires timely evaluation by a fetal cardiac specialist for possible heart block. Repeated heart rate decelerations during the third trimester can be caused by fetal hypoxia. Occasional skipped beats are typically not associated with an increased risk of structural fetal heart disease and are

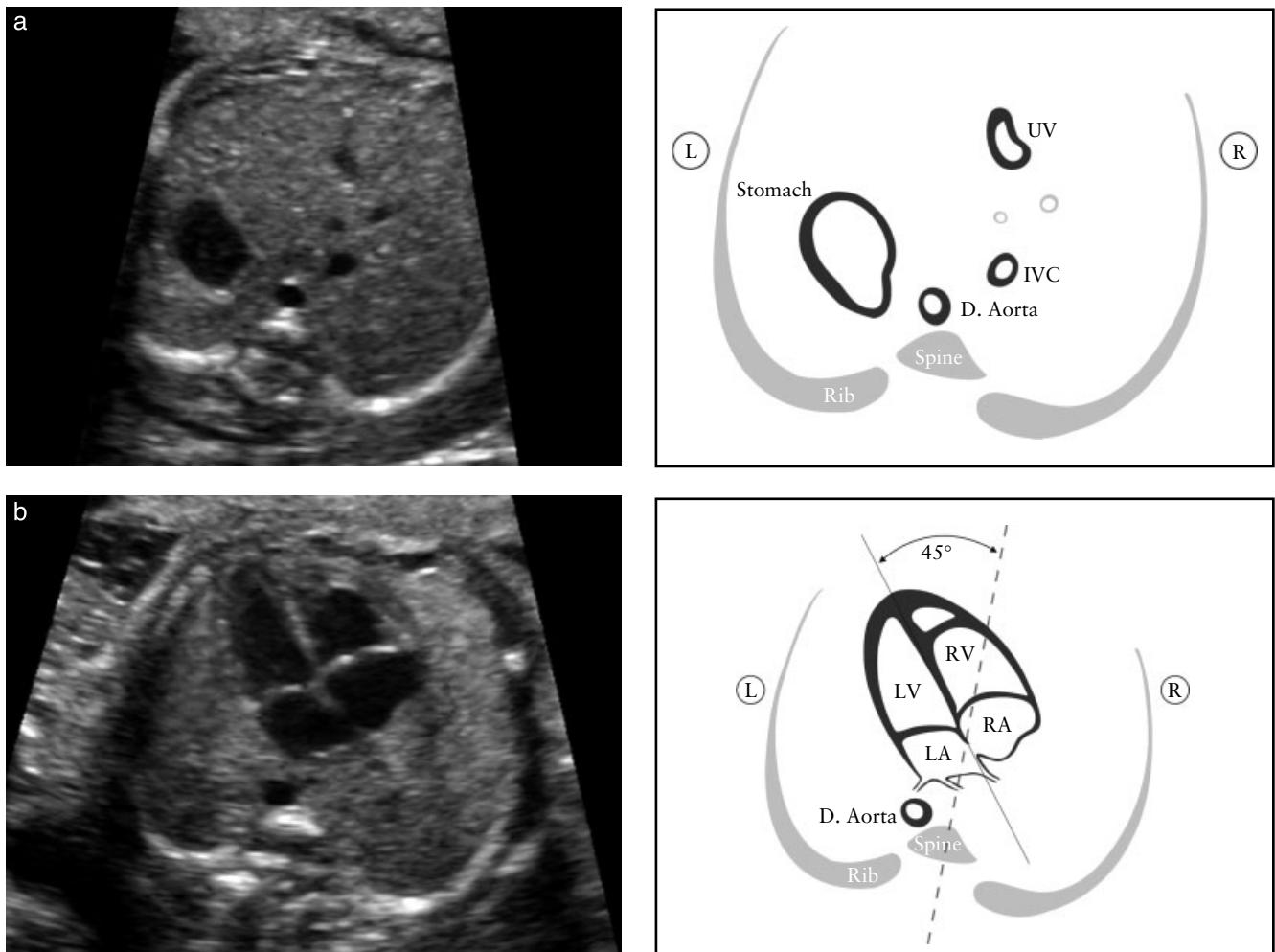


Figure 1 (a) Abdominal situs is ascertained in a transverse view of the fetal abdomen. After determining fetal laterality from position of the fetus *in utero*, the stomach should be identified on the fetal left side with the descending aorta (D. Aorta) and inferior vena cava (IVC) to the left and right sides of the spine, respectively. A short segment of the umbilical vein (UV) is seen. (b) Cardiac position and axis: the heart is mainly on the left (L) side. The cardiac apex points to the left by $45 \pm 20^\circ$ in relation to the anteroposterior axis of the chest. LA, left atrium; LV, left ventricle; R, right; RA, right atrium; RV, right ventricle.

often benign and resolve spontaneously. However, some cases may occur with clinically significant dysrhythmias and are an indication for fetal echocardiography^{52–54}. Alternatively, reassurance can be provided by more frequent Doppler auscultation and a targeted scan to rule out effusions and confirm normal views of the fetal heart. Mild tachycardia (> 160 bpm) can occur as a normal variant during fetal movement. Persistent tachycardia (≥ 180 bpm)⁵⁵, however, should be evaluated further for possible fetal hypoxia or more serious tachydysrhythmias.

Both atrial chambers normally appear similar in size and the foramen ovale flap should open into the left atrium. The lower rim of atrial septal tissue, called the septum primum, should be present. This forms part of the cardiac ‘crux’, the point where the lower part of the atrial septum meets the upper part of the ventricular septum and where the atrioventricular valves insert. Pulmonary veins can often be seen entering the left atrium and, when technically feasible, visualization of at least two of these veins is recommended.

The moderator band, a distinct muscle bundle that crosses the right ventricular cavity, is seen near the apex and helps to identify the morphological right ventricle. The left ventricular apex appears smooth and forms the apex of the heart. Both ventricles should appear similar in size and have no evidence of thickened walls. Although mild ventricular disproportion can occur as a normal variant in the third trimester of pregnancy, overt right–left asymmetry in midgestation warrants further examination⁵⁶; left-sided obstructive lesions, such as coarctation of the aorta and evolving hypoplastic left heart syndrome, are important causes of this disparity^{57,58}.

The ventricular septum should be examined carefully for cardiac wall defects, from the apex to the crux. Septal defects may be difficult to detect. The septum is best seen when the angle of insonation is perpendicular to it. When the ultrasound beam is directly parallel to the ventricular wall, a defect may be suspected falsely because of acoustic ‘drop-out’ artifact. Small septal defects (1–2 mm) can be very difficult to confirm if the ultrasound imaging system fails to provide a sufficient degree of lateral resolution,

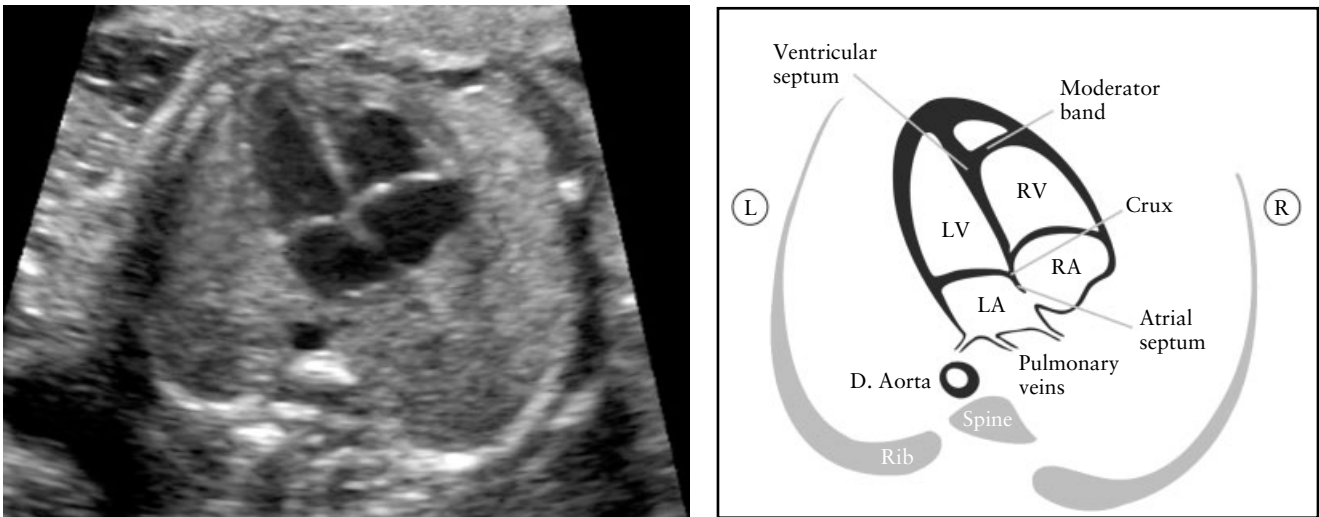


Figure 2 Four-chamber view. The key elements of the normal mid-trimester four-chamber view include heart area no more than one third of chest area, right- and left-sided structures approximately equal (chamber size and wall thickness), a patent foramen ovale with its valve in the left atrium, an intact cardiac ‘crux’ with normal offset of the two atrioventricular valves and intact ventricular septum. The morphological right ventricle (RV) is identified by the presence of the moderator band and tricuspid valve, this valve inserting more apically in the septum than does the mitral valve (normal offset). D. Aorta, descending aorta; L, left; LA, left atrium; LV, left ventricle; R, right; RA, right atrium.

especially if fetal size and position are unfavorable. However, in most cases these are of limited clinical significance and may even undergo spontaneous closure *in utero*^{59,60}.

Two distinct atrioventricular valves (right-sided, tricuspid; left-sided, mitral) should be seen to open separately and freely. The septal leaflet of the tricuspid valve is inserted into the septum closer to the apex when compared with that of the mitral valve (i.e. normal offset). Abnormal alignment of the atrioventricular valves can be a key sonographic finding for cardiac anomalies such as atrioventricular septal defect.

Outflow tract views

Views of the left and right ventricular outflow tracts (LVOT and RVOT) are considered an integral part of the fetal cardiac screening examination. It is important to ascertain normality of the two vessels, including their connection to the appropriate ventricles, their relative size and position and adequate opening of the arterial valves. It is recommended that in cases when this cannot be confirmed, further evaluation be carried out.

At the very least, examination of the outflow tracts requires that the great vessels are approximately equal in size and cross each other at right angles from their origins as they exit from the respective ventricles (normal ‘cross-over’, Appendix S1, Panel 1). A large obstetric ultrasound survey of over 18 000 fetuses⁶¹ examined the standardized practice of incorporating the four-chamber view and, when technically feasible, evaluation of the outflow tracts, into the routine 30-min examination. Most (93%) examinations that included an adequate four-chamber view were also associated with satisfactory evaluation of the outflow tracts. Non-visualization rates were: 4.2% for the LVOT, 1.6% for the RVOT and 1.3% for both outflow tracts.

Additional cross-sectional views show different aspects of the great vessels and surrounding structures, but are part of a continuous sweep starting from the RVOT and include the three-vessel (3V) view and the three vessels and trachea (3VT) view (Appendix S1, Panel 2). In a study involving nearly 3000 low-risk pregnancies examined by one operator, the 3V view and the 3VT view were added to the standard four-chamber view as part of routine screening. The average time to obtain the cardiac views was just over 2 min (135 s; SD, 20 s) but in approximately one third of cases the cardiac examination was postponed by 15–20 min due to unfavorable fetal lie (anterior spine)⁴⁶.

The evaluation of outflow tracts increases the detection rates for major cardiac malformations above those achievable by the four-chamber view alone^{20,40,42,62,63}. The inclusion of outflow tract views is more likely to identify conotruncal anomalies such as tetralogy of Fallot, transposition of the great arteries, double outlet right ventricle and truncus arteriosus^{43–46,64–69}.

Sonographic technique

Performing a transverse sweep (sweep technique) with cephalad movement of the transducer from the fetal abdomen (at the level of the standard abdominal circumference) through the four-chamber view and towards the upper mediastinum offers a systematic way of assessing the fetal heart and provides the various views through which normality of the outflow tracts views can be ascertained: LVOT, RVOT, 3V and 3VT views⁷⁰, (Figure 3). In the ideal exam, all outflow tract views can be obtained with relative ease. However, it may not be technically feasible to demonstrate all of these in every patient during routine screening. Hence, being familiar with all is desirable.

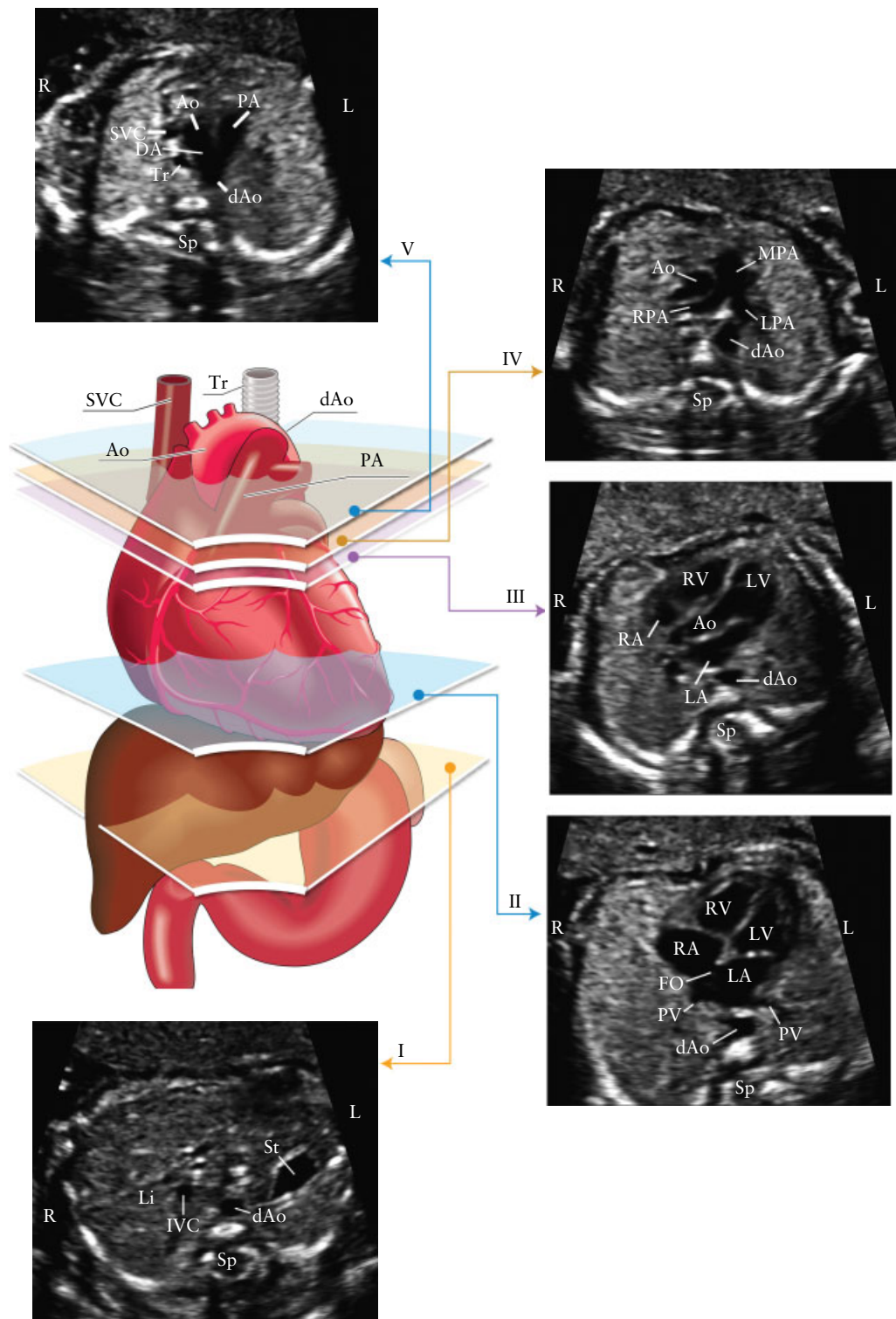


Figure 3 The five axial views for optimal fetal heart screening. The color image shows the trachea (Tr), heart and great vessels, liver and stomach, with the five planes of insonation indicated by polygons corresponding to the gray-scale images, as indicated. (I) Most caudal plane, showing the fetal stomach (St), cross-section of the descending aorta (dAo), spine (Sp) and liver (Li). (II) Four-chamber view of the fetal heart, showing the right and left ventricles (RV, LV) and atria (RA, LA), foramen ovale (FO) and pulmonary veins (PV) to the right and left of the dAo. (III) Left ventricular outflow tract view, showing the aortic root (Ao), LV, RV, LA and RA and a cross-section of the dAo. (IV) Slightly more cephalad view (right ventricular outflow tract view) showing the main pulmonary artery (MPA) and the bifurcation into the right (RPA) and left (LPA) pulmonary arteries and cross-sections of the ascending aorta (Ao) and dAo. (V) Three vessels and trachea view showing the superior vena cava (SVC), pulmonary artery (PA), ductus arteriosus (DA), transverse aortic arch (from proximal Ao to dAo) and trachea (Tr). IVC, inferior vena cava; L, left; R, right. Modified with permission from Yagel *et al.*⁷⁰.

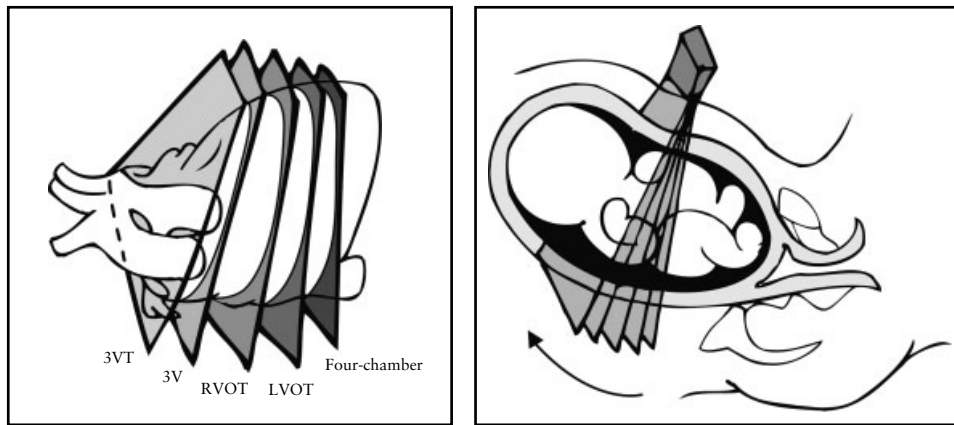


Figure 4 Fetal heart scanning technique. The four-chamber view is obtained through an axial scanning plane across the fetal chest. Cephalad tilting of the transducer from the four-chamber view towards the fetal head gives the outflow tract views sequentially: left ventricular outflow tract (LVOT), right ventricular outflow tract (RVOT), three-vessel (3V) and three vessels and trachea (3VT) views.

The LVOT and RVOT views can be obtained by sliding (or angling) the transducer towards the fetal head (sweep technique) (Figure 4), starting from a four-chamber view to obtain the normal cross-over of the aorta and main pulmonary artery at their origin. Details of the pulmonary artery bifurcation can also be seen (Appendix S1, Panels 1 and 2). Alternatively, a variation in the method for evaluating the outflow tracts in the fetus has also been described: the rotational technique⁴¹ (Appendix S2, Panel 1). From a four-chamber view of the heart, the transducer is first rotated towards the fetal right shoulder. This technique, more easily performed when the interventricular septum is perpendicular to the ultrasound beam, may require slightly more manual skills but optimizes visualization of the LVOT, especially the septo-aortic continuity. It also allows visualization of the whole ascending aorta, as opposed to only its proximal part as with the sweep technique. With both techniques, once the LVOT view is obtained, the transducer is angled cephalad until the pulmonary artery is observed with a direction almost perpendicular to that of the aorta.

Additional views of the aorta and pulmonary artery can be obtained by further sliding or tilting the transducer towards the fetal head from the RVOT. These views correspond to the 3V view and the 3VT view, in which the relationship of the two arteries with the superior vena cava and trachea is shown. The ductal arch as well as the transverse aortic arch can also be imaged at this level^{64–67}.

Left ventricular outflow tract (LVOT) view. The LVOT view confirms the presence of a great vessel originating from the morphological left ventricle (Figure 5). Continuity should be documented between the ventricular septum and the anterior wall of this vessel, the aorta. The aortic valve moves freely and should not be thickened. It is possible to trace the aorta into its arch, from which three arteries originate into the neck. However, identification of these aortic arch vessels is not considered as a routine part of the cardiac examination. The LVOT view helps to identify outlet ventricular septal defects and conotruncal

abnormalities that are not seen during examination of the four-chamber view alone.

Right ventricular outflow tract (RVOT) view. The RVOT view confirms the presence of a great vessel originating from the morphological right ventricle (Figure 6): the pulmonary artery normally arises from this ventricle and courses towards the left of the more posterior ascending aorta. It is usually slightly larger than the aortic root during fetal life and crosses the ascending aorta at almost a right angle just above its origin. At this level, as seen in Figure 6, the superior vena cava is often seen to the right of the aorta. This view is similar to the 3V view, described by Yoo *et al.*⁶⁴.

The pulmonary valve moves freely and should not be thickened. The vessel originating from the RVOT can be confirmed as the pulmonary artery only if it branches after a short course. The take-off of the right branch of the pulmonary artery comes first and the left branch subsequently. This division cannot always be seen owing to fetal position. The normal pulmonary artery continues distally towards the left side and into the ductus arteriosus that connects to the descending aorta (Figure 6 and Appendix S1).

Three-vessel (3V) view and three vessels and trachea (3VT) view. Visualization of the 3V view and 3VT view is desirable and should be attempted as part of the routine cardiac screening examination, although it may not be technically feasible to obtain them in all patients.

These two standard ultrasound planes define three vascular structures, and their relationships with each other and with the airways (trachea). Yoo *et al.*⁶⁴ described the 3V view to evaluate the pulmonary artery, ascending aorta and superior vena cava, and their relative sizes and relationships (Figure 7). Briefly, an assessment of vessel number, size, alignment and arrangement needs to be made. From left to right, the vessels are the pulmonary artery, the aorta and the superior vena cava. The pulmonary artery is the most anterior vessel and the superior vena cava is the most posterior. Their relative diameters

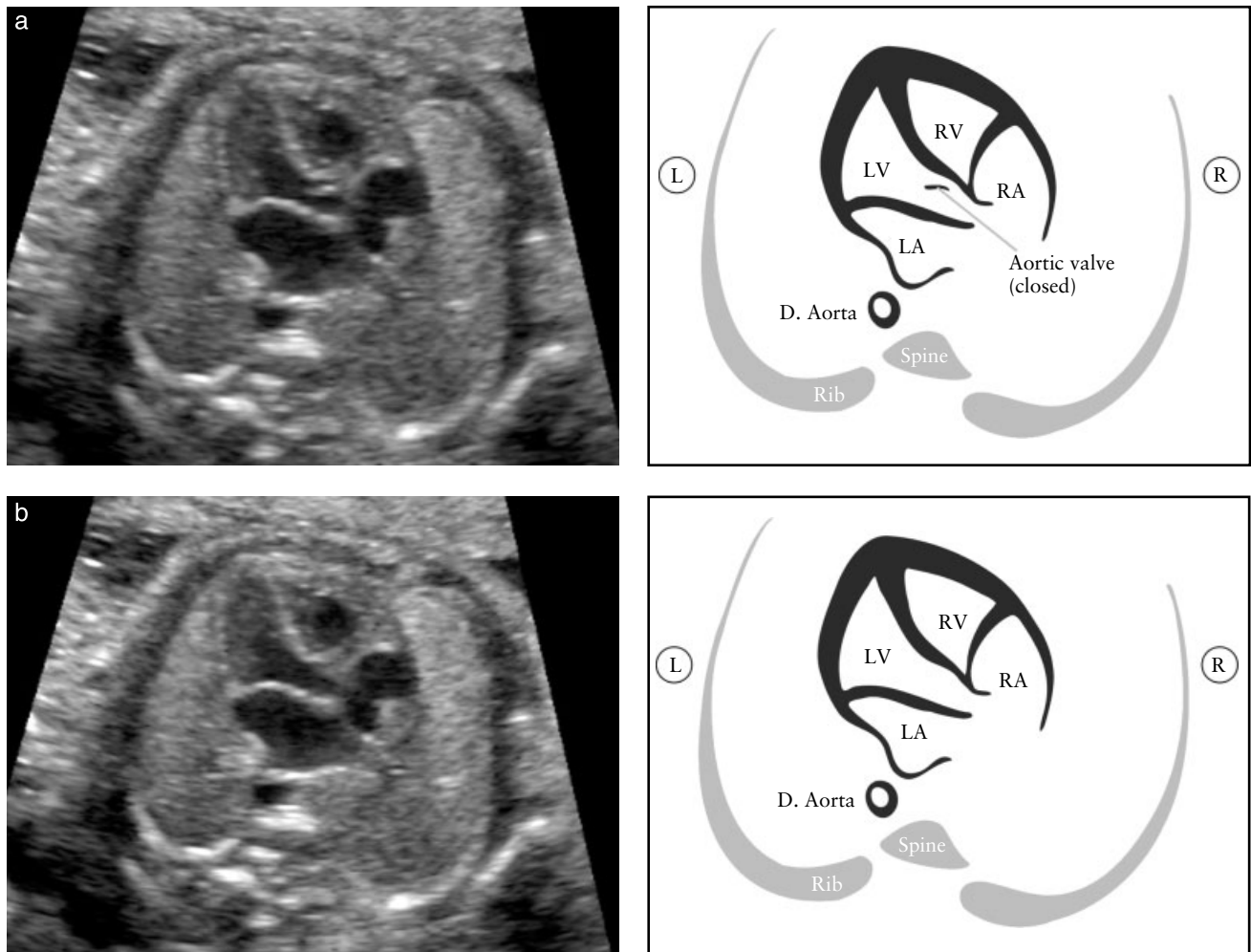


Figure 5 Left ventricular outflow tract (LVOT) view. This view shows a vessel connected to the left ventricle (LV). It is important to demonstrate continuity between the interventricular septum and the anterior wall of this vessel, which in the normal heart corresponds to the aorta. The aortic valve should not be thickened and should be shown to open freely. The aortic valve is closed in (a) and open in (b). D. Aorta, descending aorta; L, left; LA, left atrium; R, right; RA, right atrium; RV, right ventricle.

decrease from left to right, with the pulmonary artery being larger than the aorta, and the aorta larger than the superior vena cava. Typically, certain abnormalities associated with a normal four-chamber view, such as complete transposition of the great arteries, tetralogy of Fallot and pulmonary atresia with a ventricular septal defect, are likely to have an abnormal 3V view. Yagel *et al.*⁶⁷ subsequently described the 3VT view, which is a more cephalad image, in which the transverse aortic arch is better visualized ('aortic arch view') and its relationship with the trachea emphasized. The trachea is usually identified as a hyperechogenic ring surrounding a small fluid-filled space. Both the ductal and aortic arches are positioned to the left of the trachea and form a 'V' shape as they both join the descending aorta (Figure 8). The aortic arch is the most cranial of the two arches, therefore to image both arches simultaneously may require some transducer adjustments, away from the plane that is parallel to the four-chamber view. The 3VT view is likely to enable detection of lesions such as coarctation of the aorta, right aortic arch, double aortic arch and vascular rings.

COLOR FLOW DOPPLER

Although the use of color flow Doppler is not considered mandatory in these Guidelines, becoming familiar with its use and adding it to routine screening is encouraged⁷¹. Color flow mapping is an integral part of performing fetal echocardiography and its role in the diagnosis of CHD cannot be underestimated. Color Doppler imaging can also be used during routine screening, if the operator feels competent with its use. Color flow mapping may facilitate imaging of the various cardiac structures as well as highlighting abnormal blood flow patterns. It may also constitute a valuable tool in the evaluation of cardiac anatomy in obese patients⁷² and may further improve detection rates of major CHD in low-risk pregnancies^{46,73}.

Optimal color Doppler settings include the use of a narrow color box (region of interest) as this has the greatest impact on frame rate, appropriate pulse repetition frequency, low color persistence and adequate gain settings to display flow across valves and vessels (See Appendix S2).

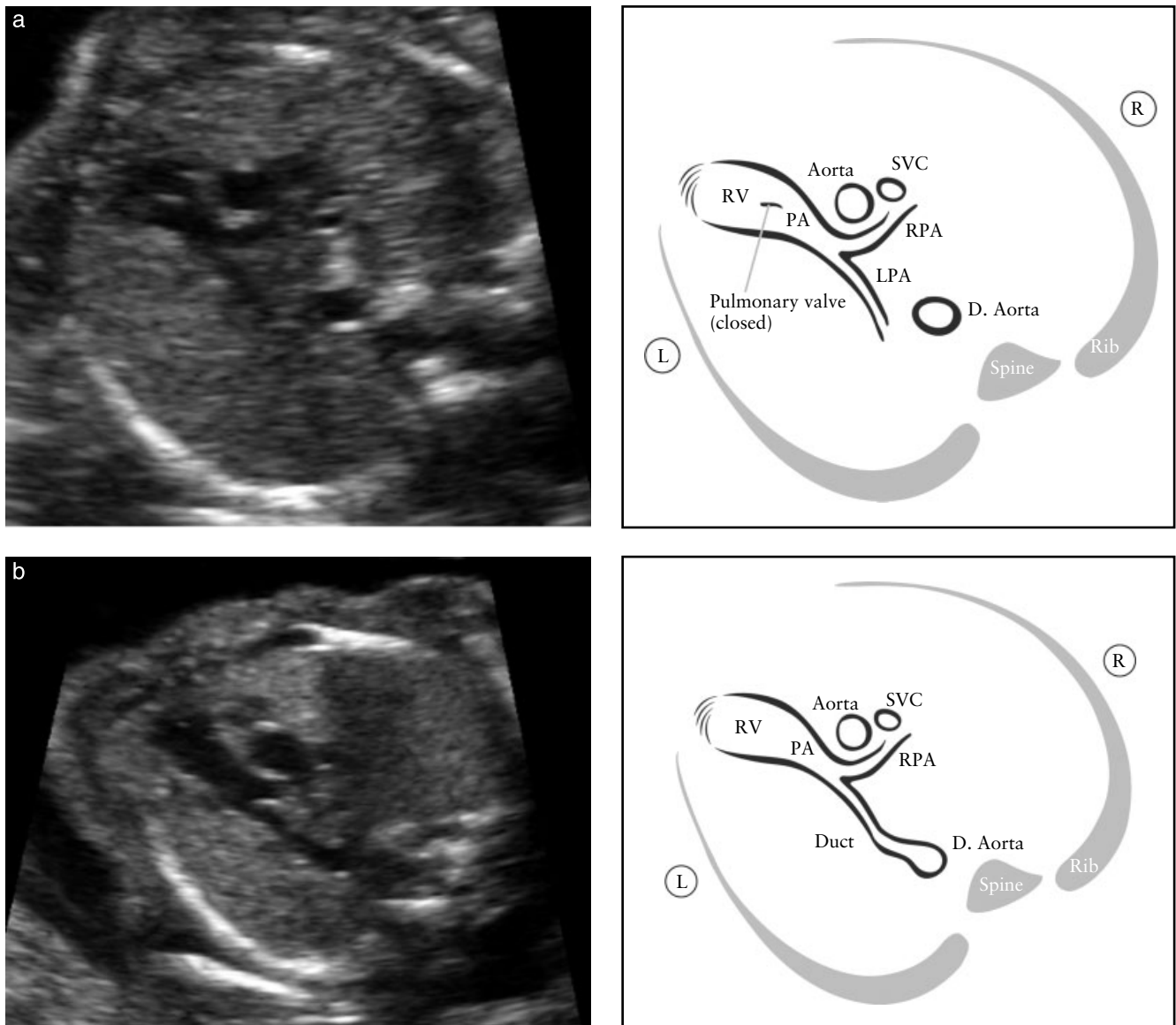


Figure 6 Right ventricular outflow tract (RVOT) view. This view shows a vessel connected to the right ventricle (RV). In the normal heart this vessel crosses over the aorta, which helps in identifying it as the main pulmonary artery (PA). The pulmonary valve should not be thickened and should open freely. In (a), the bifurcation of the PA into both pulmonary branches can be seen. The pulmonary valve is closed. In (b), the plane of insonation is slightly more cephalad. The PA, right pulmonary artery (RPA) and arterial duct are seen. D. Aorta, descending aorta; L, left; LPA, left pulmonary artery; R, right; SVC, superior vena cava.

FETAL ECHOCARDIOGRAPHY

A fetal echocardiogram should be performed if CHD is suspected, if the normal four-chamber and outflow tract views described above cannot be obtained at the time of screening or if recognized risk factors indicate increased risk for CHD. Specific details of this specialized procedure have been published previously²⁶ and are not within the scope of this article. A high proportion of cases of CHD detectable prenatally occurs in patients without any risk factors or extracardiac anomalies⁶³; hence the importance of screening. Healthcare practitioners, however, should be familiar with some of the reasons why patients should be referred for a comprehensive cardiac evaluation⁷⁴. For example, increased nuchal translucency

thickness of greater than 3.5 mm at 11–14 weeks' gestation is an indication for a detailed cardiac evaluation even if the measurement subsequently falls into the normal range^{75–78}.

Fetal echocardiography should be performed by specialists who are familiar with the prenatal diagnosis of CHD. In addition to the information provided by the basic screening examination, a detailed analysis of cardiac structure and function further characterizes viscerotrial situs, systemic and pulmonary venous connections, foramen ovale mechanism, atrioventricular connection, ventriculoarterial connection, great vessel relationships and sagittal views of the aortic and ductal arches.

Other conventional sonographic techniques can be used to study the fetal heart. For example, Doppler

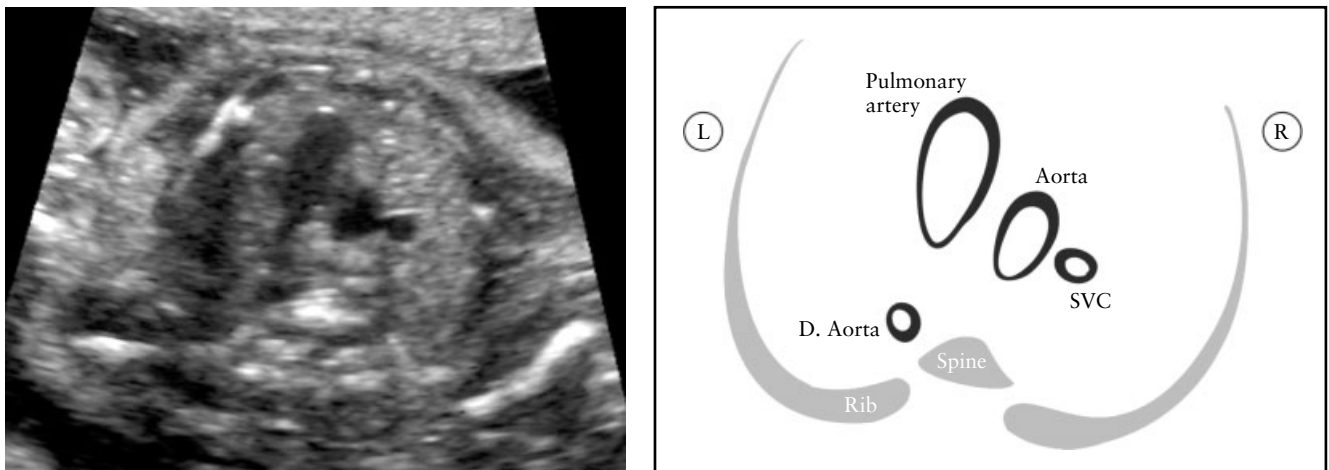


Figure 7 Three-vessel (3V) view. This view best demonstrates the relationship between the pulmonary artery, aorta and superior vena cava (SVC) in the upper mediastinum. It is important to note the correct position and alignment of the three vessels as well as their relative size. The pulmonary artery, to the left, is the largest of the three and the most anterior, whereas the SVC is the smallest and most posterior. D. Aorta, descending aorta.

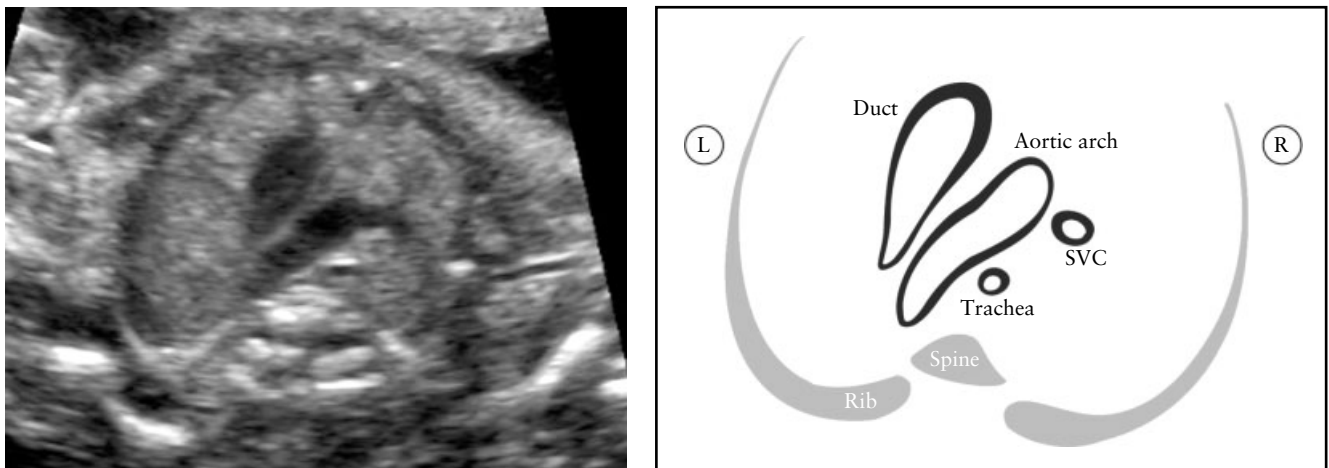


Figure 8 Three vessels and trachea (3VT) view. This view best demonstrates the transverse aortic arch and its relationship with the trachea. In the normal heart, both the aortic arch and the ductal arch are located to the left of the trachea, in a 'V'-shaped configuration. L, left; R, right; SVC, superior vena cava.

ultrasonography can measure blood flow velocity or identify abnormal flow patterns across valves and within heart chambers. M-mode echocardiography is also an important method for analyzing cardiac rhythm, ventricular function and myocardial wall thickness. Newer techniques that have become more widely available, such as tissue Doppler and volume sonography (three-dimensional (3D)/4D/spatiotemporal image correlation (STIC)), can also be incorporated into a more detailed anatomical and functional assessment of the fetal heart. 4D fetal echocardiography has been shown to contribute to the diagnostic assessment in cases of complex heart defects including conotruncal malformations, aortic arch abnormalities and abnormal pulmonary venous return^{79–81}. Additional ultrasound modalities, such as speckle tracking, are currently being used mainly in research settings but may become

an important clinical tool in evaluating fetal cardiac function.

GUIDELINE AUTHORS

J. S. Carvalho, Royal Brompton Hospital, London, UK; Fetal Medicine Unit, St George's Hospital & St George's University of London, London, UK

L. D. Allan, Harris Birthright Research Centre for Fetal Medicine, King's College Hospital, London, UK

R. Chaoui, Center for Prenatal Diagnosis and Human Genetics, Friedrichstrasse 147, Berlin, Germany

J. A. Copel, Obstetrics, Gynecology and Reproductive Sciences, Yale University School of Medicine, New Haven, CT, USA

G. R. DeVore, Fetal Diagnostic Center, South Fair Oaks Ave, Pasadena, CA, USA; Department of Obstetrics and

Gynecology, David Geffen School of Medicine at UCLA, Los Angeles, CA, USA

K. Hecher, Department of Obstetrics and Fetal Medicine, University Medical Center Hamburg-Eppendorf, Hamburg, Germany

W. Lee, Texas Children's Pavilion for Women, Department of Obstetrics and Gynecology, Baylor College of Medicine, Houston, TX, USA

H. Munoz, Fetal Medicine Unit, Obstetric & Gynecology Department, University of Chile, Santiago, Chile; Clinica las Condes, Santiago, Chile

D. Paladini, Fetal Medicine and Cardiology Unit, Department of Obstetrics and Gynecology, University Federico II of Naples, Naples, Italy

B. Tutschek, Center for Fetal Medicine and Gynecological Ultrasound, Basel, Switzerland; Medical Faculty, Heinrich Heine University, Düsseldorf, Germany

S. Yagel, Division of Obstetrics and Gynecology, Hadassah-Hebrew University Medical Centers, Jerusalem, Israel

CITATION

These Guidelines should be cited as: 'Carvalho JS, Allan LD, Chaoui R, Copel JA, DeVore GR, Hecher K, Lee W, Munoz H, Paladini D, Tutschek B, Yagel S. ISUOG practice guidelines (updated): sonographic screening examination of the fetal heart. *Ultrasound Obstet Gynecol* 2013; **41**: 348–359.'

REFERENCES

- Cardiac screening examination of the fetus: guidelines for performing the 'basic' and 'extended basic' cardiac scan. *Ultrasound Obstet Gynecol* 2006; **27**: 107–113.
- Antenatal care: routine care for the healthy pregnant woman. <http://www.nice.org.uk/CG062> [Accessed 23 October 2011].
- 18 + 0 to 20 + 6 weeks fetal anomaly scan – National standards and guidance for England 2010. <http://fetalanomaly.screening.nhs.uk/standardsandpolicies2010> [Accessed 26 November 2011].
- Ultrasound Screening: Supplement to *Ultrasound Screening for Fetal Abnormalities*. <http://www.rcog.org.uk/print/womens-health/clinical-guidance/ultrasound-screeningRCOG2011> [Accessed 27 November 2011].
- Israel Society of Ultrasound in Obstetrics and Gynecology. <http://www.isuog.org.il/main/siteNew/?page=&action=sidLink&stld=301> [Accessed 6 February 2012].
- Ferencz C, Rubin JD, McCarter RJ, Brenner JI, Neill CA, Perry LW, Hepner SI, Downing JW. Congenital heart disease: prevalence at livebirth. The Baltimore-Washington Infant Study. *Am J Epidemiol* 1985; **121**: 31–36.
- Meberg A, Otterstad JE, Froland G, Lindberg H, Sorland SJ. Outcome of congenital heart defects—a population-based study. *Acta Paediatr* 2000; **89**: 1344–1351.
- Cuneo BF, Curran LF, Davis N, Elrad H. Trends in prenatal diagnosis of critical cardiac defects in an integrated obstetric and pediatric cardiac imaging center. *J Perinatol* 2004; **24**: 674–678.
- Rosano A, Botto LD, Botting B, Mastroiacovo P. Infant mortality and congenital anomalies from 1950 to 1994: an international perspective. *J Epidemiol Community Health* 2000; **54**: 660–666.
- Crane JP, LeFevre ML, Winborn RC, Evans JK, Ewigman BG, Bain RP, Frigoletto FD, McNellis D. A randomized trial of prenatal ultrasonographic screening: impact on the detection, management, and outcome of anomalous fetuses. The RADIUS Study Group. *Am J Obstet Gynecol* 1994; **171**: 392–399.
- Abu-Harb M, Hey E, Wren C. Death in infancy from unrecognized congenital heart disease. *Arch Dis Child* 1994; **71**: 3–7.
- Bonnet D, Coltri A, Butera G, Fermont L, Le Bidois J, Kachaner J, Sidi D. Detection of transposition of the great arteries in fetuses reduces neonatal morbidity and mortality. *Circulation* 1999; **99**: 916–918.
- Tworetzky W, McElhinney DB, Reddy VM, Brook MM, Hanley FL, Silverman NH. Improved surgical outcome after fetal diagnosis of hypoplastic left heart syndrome. *Circulation* 2001; **103**: 1269–1273.
- Andrews R, Tulloh R, Sharland G, Simpson J, Rollings S, Baker E, Qureshi S, Rosenthal E, Austin C, Anderson D. Outcome of staged reconstructive surgery for hypoplastic left heart syndrome following antenatal diagnosis. *Arch Dis Child* 2001; **85**: 474–477.
- Franklin O, Burch M, Manning N, Sleeman K, Gould S, Archer N. Prenatal diagnosis of coarctation of the aorta improves survival and reduces morbidity. *Heart* 2002; **87**: 67–69.
- Tworetzky W, Wilkins-Haug L, Jennings RW, Van Der Velde ME, Marshall AC, Marx GR, Colan SD, Benson CB, Lock JE, Perry SB. Balloon dilation of severe aortic stenosis in the fetus: potential for prevention of hypoplastic left heart syndrome: candidate selection, technique, and results of successful intervention. *Circulation* 2004; **110**: 2125–2131.
- Simpson LL. Screening for congenital heart disease. *Obstet Gynecol Clin North Am* 2004; **31**: 51–59.
- DeVore GR, Medearis AL, Bear MB, Horenstein J, Platt LD. Fetal echocardiography: factors that influence imaging of the fetal heart during the second trimester of pregnancy. *J Ultrasound Med* 1993; **12**: 659–663.
- Sharland GK, Allan LD. Screening for congenital heart disease prenatally. Results of a 2 1/2-year study in the South East Thames Region. *Br J Obstet Gynaecol* 1992; **99**: 220–225.
- Carvalho JS, Mavrides E, Shinebourne EA, Campbell S, Thilaganathan B. Improving the effectiveness of routine prenatal screening for major congenital heart defects. *Heart* 2002; **88**: 387–391.
- Hunter S, Heads A, Wyllie J, Robson S. Prenatal diagnosis of congenital heart disease in the northern region of England: benefits of a training programme for obstetric ultrasonographers. *Heart* 2000; **84**: 294–298.
- Lee W. Performance of the basic fetal cardiac ultrasound examination. *J Ultrasound Med* 1998; **17**: 601–607.
- AIUM. AIUM Practice Guideline for the performance of an antepartum obstetric ultrasound examination. *J Ultrasound Med* 2003; **22**: 1116–1125.
- ACR Practice Guideline for the performance of antepartum obstetrical ultrasound. *Am Coll Radiol* 2003: 689–695.
- ACOG Practice Bulletin No. 58. Ultrasonography in pregnancy. *Obstet Gynecol* 2004; **104**: 1449–1458.
- Lee W, Allan L, Carvalho JS, Chaoui R, Copel J, DeVore G, Hecher K, Munoz H, Nelson T, Paladini D, Yagel S; ISUOG Fetal Echocardiography Task Force. ISUOG consensus statement: what constitutes a fetal echocardiogram? *Ultrasound Obstet Gynecol* 2008; **32**: 239–242.
- Tegnander E, Eik-Nes SH, Johansen OJ, Linker DT. Prenatal detection of heart defects at the routine fetal examination at 18 weeks in a non-selected population. *Ultrasound Obstet Gynecol* 1995; **5**: 372–380.
- Chaoui R. The four-chamber view: four reasons why it seems to fail in screening for cardiac abnormalities and suggestions to improve detection rate. *Ultrasound Obstet Gynecol* 2003; **22**: 3–10.
- Tegnander E, Eik-Nes SH, Linker DT. Incorporating the four-chamber view of the fetal heart into the second-trimester routine fetal examination. *Ultrasound Obstet Gynecol* 1994; **4**: 24–28.

30. Achiron R, Rotstein Z, Lipitz S, Mashiach S, Hegesh J. First-trimester diagnosis of fetal congenital heart disease by transvaginal ultrasonography. *Obstet Gynecol* 1994; **84**: 69–72.
31. Yagel S, Weissman A, Rotstein Z, Manor M, Hegesh J, Anteby E, Lipitz S, Achiron R. Congenital heart defects: natural course and in utero development. *Circulation* 1997; **96**: 550–555.
32. Rustico MA, Benettoni A, D'Ottavio G, Fischer-Tamaro L, Conoscenti GC, Meir Y, Natale R, Bussani R, Mandruzzato GP. Early screening for fetal cardiac anomalies by transvaginal echocardiography in an unselected population: the role of operator experience. *Ultrasound Obstet Gynecol* 2000; **16**: 614–619.
33. Carvalho JS. Fetal heart scanning in the first trimester. *Prenat Diagn* 2004; **24**: 1060–1067.
34. Carvalho JS, Moscoso G, Tekay A, Campbell S, Thilaganathan B, Shinebourne EA. Clinical impact of first and early second trimester fetal echocardiography on high risk pregnancies. *Heart* 2004; **90**: 921–926.
35. Huggon IC, Ghi T, Cook AC, Zosmer N, Allan LD, Nicolaides KH. Fetal cardiac abnormalities identified prior to 14 weeks' gestation. *Ultrasound Obstet Gynecol* 2002; **20**: 22–29.
36. Schwarzler P, Senat MV, Holden D, Bernard JP, Masroor T, Ville Y. Feasibility of the second-trimester fetal ultrasound examination in an unselected population at 18, 20 or 22 weeks of pregnancy: a randomized trial. *Ultrasound Obstet Gynecol* 1999; **14**: 92–97.
37. Paladini D, Vassallo M, Tartaglione A, Lapadula C, Martinelli P. The role of tissue harmonic imaging in fetal echocardiography. *Ultrasound Obstet Gynecol* 2004; **23**: 159–164.
38. Allan LD, Crawford DC, Chita SK, Tynan MJ. Prenatal screening for congenital heart disease. *Br Med J (Clin Res Ed)* 1986; **292**: 1717–1719.
39. Copel JA, Pilu G, Green J, Hobbins JC, Kleinman CS. Fetal echocardiographic screening for congenital heart disease: the importance of the four-chamber view. *Am J Obstet Gynecol* 1987; **157**: 648–655.
40. Kirk JS, Riggs TW, Comstock CH, Lee W, Yang SS, Weinhouse E. Prenatal screening for cardiac anomalies: the value of routine addition of the aortic root to the four-chamber view. *Obstet Gynecol* 1994; **84**: 427–431.
41. DeVore GR. The aortic and pulmonary outflow tract screening examination in the human fetus. *J Ultrasound Med* 1992; **11**: 345–348.
42. Achiron R, Glaser J, Gelernter I, Hegesh J, Yagel S. Extended fetal echocardiographic examination for detecting cardiac malformations in low risk pregnancies. *BMJ* 1992; **304**: 671–674.
43. Achiron R, Rotstein Z, Hegesh J, Bronshtein M, Zimand S, Lipitz S, Yagel S. Anomalies of the fetal aortic arch: a novel sonographic approach to *in-utero* diagnosis. *Ultrasound Obstet Gynecol* 2002; **20**: 553–557.
44. Yoo SJ, Min JY, Lee YH, Roman K, Jaeggi E, Smallhorn J. Fetal sonographic diagnosis of aortic arch anomalies. *Ultrasound Obstet Gynecol* 2003; **22**: 535–546.
45. Barboza JM, Dajani NK, Glenn LG, Angtuaco TL. Prenatal diagnosis of congenital cardiac anomalies: a practical approach using two basic views. *Radiographics* 2002; **22**: 1125–1137; discussion 1137–1138.
46. Del Bianco A, Russo S, Lacerenza N, Rinaldi M, Rinaldi G, Nappi L, Greco P. Four chamber view plus three-vessel and trachea view for a complete evaluation of the fetal heart during the second trimester. *J Perinat Med* 2006; **34**: 309–312.
47. Di Salvo DN, Brown DL, Doubilet PM, Benson CB, Frates MC. Clinical significance of isolated fetal pericardial effusion. *J Ultrasound Med* 1994; **13**: 291–293.
48. Yoo SJ, Min JY, Lee YH. Normal pericardial fluid in the fetus: color and spectral Doppler analysis. *Ultrasound Obstet Gynecol* 2001; **18**: 248–252.
49. Comstock CH. Normal fetal heart axis and position. *Obstet Gynecol* 1987; **70**: 255–259.
50. Smith RS, Comstock CH, Kirk JS, Lee W. Ultrasonographic left cardiac axis deviation: a marker for fetal anomalies. *Obstet Gynecol* 1995; **85**: 187–191.
51. ACOG Practice Bulletin No. 106: Intrapartum fetal heart rate monitoring: nomenclature, interpretation, and general management principles. *Obstet Gynecol* 2009; **114**: 192–202.
52. Copel JA, Liang RL, Demasio K, Ozeren S, Kleinman CS. The clinical significance of the irregular fetal heart rhythm. *Am J Obstet Gynecol* 2000; **182**: 813–817.
53. Simpson JL, Yates RW, Sharland GK. Irregular heart rate in the fetus: not always benign. *Cardiol Young* 1996; **6**: 28–31.
54. Cuneo BF, Strasburger JF, Wakai RT, Ovadia M. Conduction system disease in fetuses evaluated for irregular cardiac rhythm. *Fetal Diagn Ther* 2006; **21**: 307–313.
55. Srinivasan S, Strasburger J. Overview of fetal arrhythmias. *Curr Opin Pediatr* 2008; **20**: 522–531.
56. Kirk JS, Comstock CH, Lee W, Smith RS, Riggs TW, Weinhouse E. Fetal cardiac asymmetry: a marker for congenital heart disease. *Obstet Gynecol* 1999; **93**: 189–192.
57. Sharland GK, Chan KY, Allan LD. Coarctation of the aorta: difficulties in prenatal diagnosis. *Br Heart J* 1994; **71**: 70–75.
58. Hornberger LK, Sanders SP, Rein AJ, Spevak PJ, Parness IA, Colan SD. Left heart obstructive lesions and left ventricular growth in the midtrimester fetus. A longitudinal study. *Circulation* 1995; **92**: 1531–1538.
59. Paladini D, Palmieri S, Lamberti A, Teodoro A, Martinelli P, Nappi C. Characterization and natural history of ventricular septal defects in the fetus. *Ultrasound Obstet Gynecol* 2000; **16**: 118–122.
60. Axt-Fliedner R, Schwarze A, Smrcek J, Germer U, Krapp M, Gembruch U. Isolated ventricular septal defects detected by color Doppler imaging: evolution during fetal and first year of postnatal life. *Ultrasound Obstet Gynecol* 2006; **27**: 266–273.
61. Vettriano IM, Lee W, Bronshtein RA, Comstock CH. Sonographic evaluation of the ventricular cardiac outflow tracts. *J Ultrasound Med* 2005; **24**: 566.
62. Bromley B, Estroff JA, Sanders SP, Parad R, Roberts D, Frigoletto FD, Jr., Benacerraf BR. Fetal echocardiography: accuracy and limitations in a population at high and low risk for heart defects. *Am J Obstet Gynecol* 1992; **166**: 1473–1481.
63. Stumpflen I, Stumpflen A, Wimmer M, Bernaschek G. Effect of detailed fetal echocardiography as part of routine prenatal ultrasonographic screening on detection of congenital heart disease. *Lancet* 1996; **348**: 854–857.
64. Yoo SJ, Lee YH, Kim ES, Ryu HM, Kim MY, Choi HK, Cho KS, Kim A. Three-vessel view of the fetal upper mediastinum: an easy means of detecting abnormalities of the ventricular outflow tracts and great arteries during obstetric screening. *Ultrasound Obstet Gynecol* 1997; **9**: 173–182.
65. Yoo SJ, Lee YH, Cho KS. Abnormal three-vessel view on sonography: a clue to the diagnosis of congenital heart disease in the fetus. *AJR Am J Roentgenol* 1999; **172**: 825–830.
66. Vinals F, Heredia F, Giuliano A. The role of the three vessels and trachea view (3VT) in the diagnosis of congenital heart defects. *Ultrasound Obstet Gynecol* 2003; **22**: 358–367.
67. Yagel S, Arbel R, Anteby EY, Raveh D, Achiron R. The three vessels and trachea view (3VT) in fetal cardiac scanning. *Ultrasound Obstet Gynecol* 2002; **20**: 340–345.
68. Tongsong T, Tongprasert F, Srisupundit K, Luewan S. The complete three-vessel view in prenatal detection of congenital heart defects. *Prenat Diagn* 2010; **30**: 23–29.
69. Berg C, Gembruch U, Geipel A. Outflow tract views in two-dimensional fetal echocardiography - part ii. *Ultraschall Med* 2009; **30**: 230–251.
70. Yagel S, Cohen SM, Achiron R. Examination of the fetal heart by five short-axis views: a proposed screening method for comprehensive cardiac evaluation. *Ultrasound Obstet Gynecol* 2001; **17**: 367–369.
71. Chaoui R, McEwing R. Three cross-sectional planes for fetal color Doppler echocardiography. *Ultrasound Obstet Gynecol* 2003; **21**: 81–93.

72. Paladini D. Sonography in obese and overweight pregnant women: clinical, medicolegal and technical issues. *Ultrasound Obstet Gynecol* 2009; 33: 720–729.
73. Nadel AS. Addition of color Doppler to the routine obstetric sonographic survey aids in the detection of pulmonic stenosis. *Fetal Diagn Ther* 2010; 28: 175–179.
74. Small M, Copel JA. Indications for fetal echocardiography. *Pediatr Cardiol* 2004; 25: 210–222.
75. Hyett J, Moscoso G, Papapanagiotou G, Perdu M, Nicolaides KH. Abnormalities of the heart and great arteries in chromosomally normal fetuses with increased nuchal translucency thickness at 11–13 weeks of gestation. *Ultrasound Obstet Gynecol* 1996; 7: 245–250.
76. Hyett JA, Perdu M, Sharland GK, Snijders RS, Nicolaides KH. Increased nuchal translucency at 10–14 weeks of gestation as a marker for major cardiac defects. *Ultrasound Obstet Gynecol* 1997; 10: 242–246.
77. Mavrides E, Cobian-Sanchez F, Tekay A, Moscoso G, Campbell S, Thilaganathan B, Carvalho JS. Limitations of using first-trimester nuchal translucency measurement in routine screening for major congenital heart defects. *Ultrasound Obstet Gynecol* 2001; 17: 106–110.
78. Ghi T, Huggon IC, Zosmer N, Nicolaides KH. Incidence of major structural cardiac defects associated with increased nuchal translucency but normal karyotype. *Ultrasound Obstet Gynecol* 2001; 18: 610–614.
79. Paladini D, Volpe P, Sglavo G, Vassallo M, De Robertis V, Marasini M, Russo MG. Transposition of the great arteries in the fetus: assessment of the spatial relationships of the arterial trunks by four-dimensional echocardiography. *Ultrasound Obstet Gynecol* 2008; 31: 271–276.
80. Volpe P, Campobasso G, De Robertis V, Di Paolo S, Caruso G, Stanziano A, Volpe N, Gentile M. Two- and four-dimensional echocardiography with B-flow imaging and spatiotemporal image correlation in prenatal diagnosis of isolated total anomalous pulmonary venous connection. *Ultrasound Obstet Gynecol* 2007; 30: 830–837.
81. Volpe P, Tuo G, De Robertis V, Campobasso G, Marasini M, Tempesta A, Gentile M, Rembouskos G. Fetal interrupted aortic arch: 2D-4D echocardiography, associations and outcome. *Ultrasound Obstet Gynecol* 2010; 35: 302–309.

SUPPORTING INFORMATION ON THE INTERNET

The following supporting information may be found in the online version of this article:



Appendix S1 Additional B-mode panels: outflow tracts

Appendix S2 Color flow panels

(Guideline review date: December 2015)